Excellent long-term survivorship of a dual mobility acetabular system

Olivier Bonnard[1], Alain Cypres[1], Arnaud Fiquet[1], Philippe Girardin[1], David Fitch[2], Philippe Bauchu[1], Daniel Noyer[1], Christophe Roy[1]

Disclosures

[1]Receives royalties from one or more devices used in study

[2]Employee of manufacturer of device used in study

Groupe GILES

Conception

- POLARCUP (1999) and POLARSTEM (2002) were created by Groupe GILES, ex-assistants of Pr Gilles Bousquet.
- According to our experience, we found out that the contact between the neck of the stem and the insert caused problems.
- The products were created as a whole system to avoid these complications.
- The insert has a chamfer and the neck of the stem is polished.

POLARCUP Dual Mobility System
(Smith & Nephew, Baar, Switzerland)

Conception

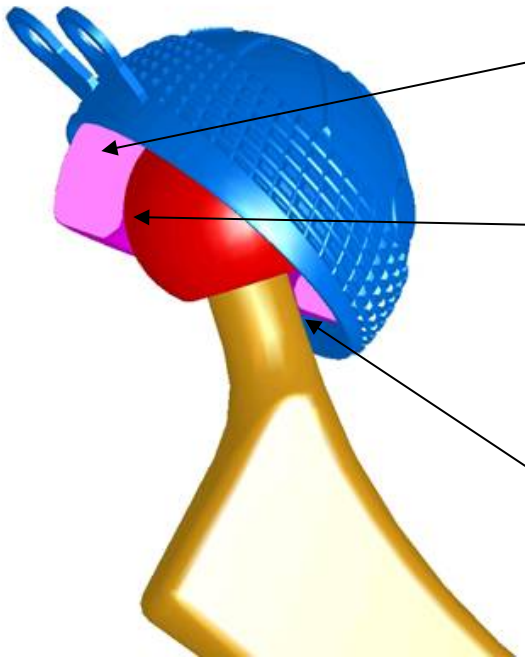

Articulation
insert / cup

+

Articulation
head / insert

= dual mobility

Articulation neck / stem

= triple articulation

Introduction

- Total hip replacement (THR) remains one of the most successful orthopaedic surgeries, but dislocation remains a common reason for revision.
- A potential option for preventing dislocations in both primary and revision THR is the use of dual mobility acetabular systems.
- One such dual mobility system is the POLARCUP, that allows for conventional or highly cross-linked polyethylene liners articulating with either ceramicised metal, ceramic, or cobalt chrome femoral heads.
- The purpose of this study was to report outcomes associated with a cementless dual mobility system used in a primary THR setting at a minimum of 10 years follow-up.

POLARCUP Dual Mobility System
(Smith & Nephew, Baar, Switzerland)

Patients and Methods

- We retrospectively reviewed 502 consecutive THRs performed at 3 centers between 2002 and 2005
- All patients were implanted with a dual-mobility acetabular system (POLARCUP, Smith & Nephew, Baar Switzerland) and a triple taper cementless femoral stem (POLARSTEM, Smith & Nephew Inc., Baar, Switzerland)
- Patients charts were reviewed for available Merle D'Aubigne Scores, radiographs, and complications/revisions
- All living, non-revised patients were then invited for a single prospective visit that included WOMAC, Merle D' Aubigne Scores, and standard radiographs

Results

- Patient Demographics

N Hips	502
Female/Male	247 / 255
Mean Age At Surgery	68.7 years (range, 29-92)
Diagnosis for Procedure	
Osteoarthritis	86.0%
Avascular Necrosis	6.2%
Dysplasia/DDH	3.3%
Rheumatoid Arthritis	2.1%
Femoral Neck Fracture	0.8%
Post-traumatic Arthritis	0.8%
Other	0.8%

Results

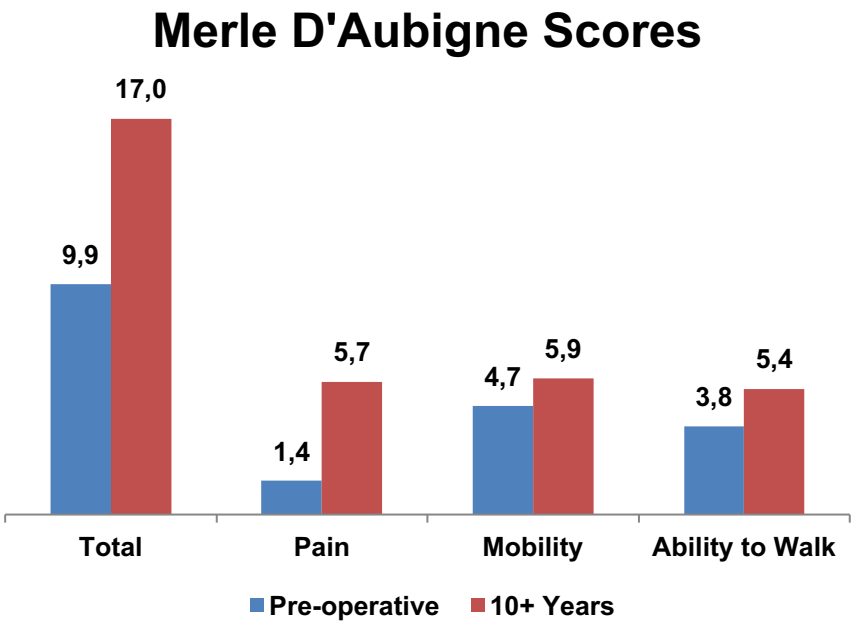
Merle D'Aubigne Scores
17,0
9,9
5,7
1,4
5,9
4,7
5,4
3,8
Total
Pain
Mobility
Ability to Walk
Pre-operative
10+ Years

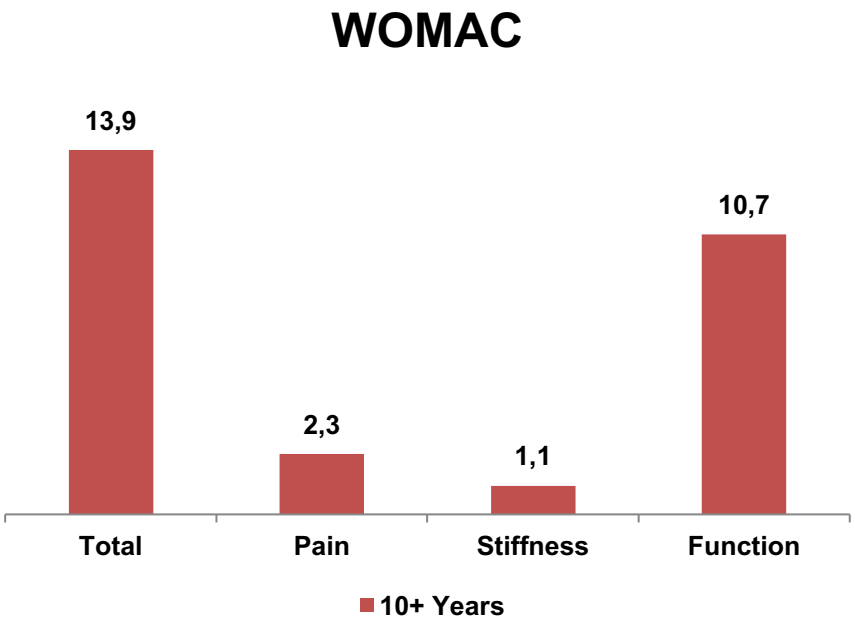
WOMAC
13,9
2,3
1,1
10,7
Total
Pain
Stiffness
Function
10+ Years

Results

Radiographic Outcomes at 10+ years

- 1 (0.4%) case of cup migration
- No signs of stem subsidence
- 1 (0.4%) case of acetabular osteolysis
- 3 (1.2%) subjects with signs of bone osteolysis
- Heterotopic Ossification
  - Grade I – 25 (10.3%)
  - Grade II – 6 (2.5%)
  - Grade III – 11 (4.5%)

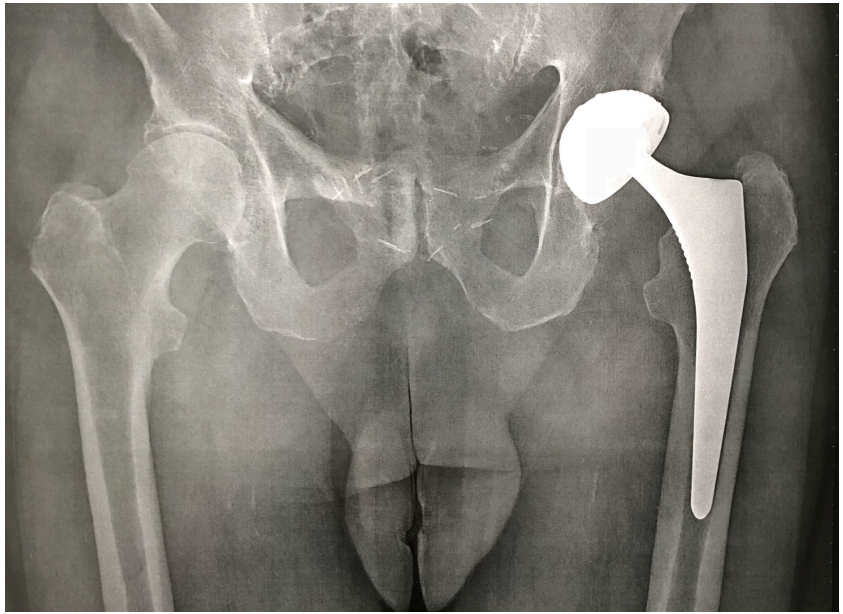

Results

- The Kaplan-Meier Survivorship Estimate at 11.9 years follow-up was 98.7% (95% CI, 96.6-99.5) with revision of the dual mobility acetabular system for any reason as the endpoint

- There were 15 revisions of the dual mobility acetabular component
  - 14 for aseptic loosening
  - 1 secondary to fracture of the femur

Conclusions

This retrospective study shows that this dual mobility system can be safely used in osteoarthritis patients aged 30 to 90 years.

Thank You

Groupe GILES